



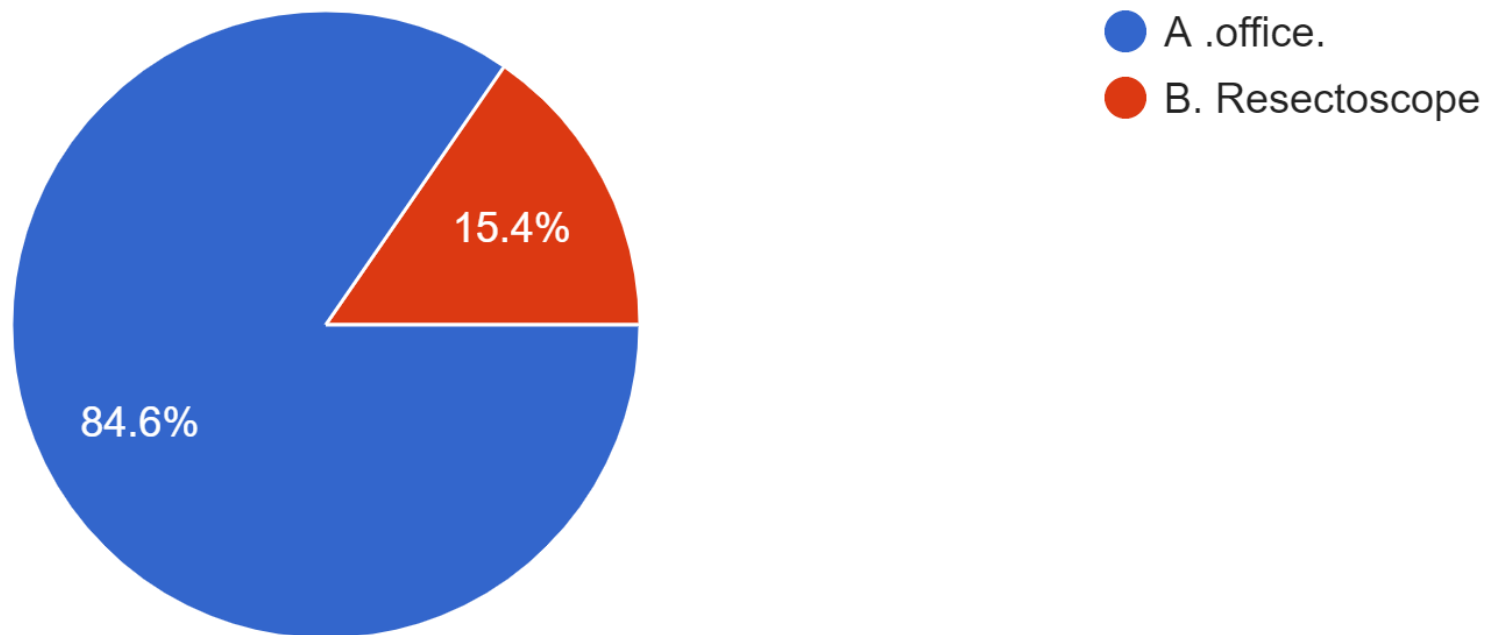
# EFRE Hysteroscopy survey

Please Scan the QR Code



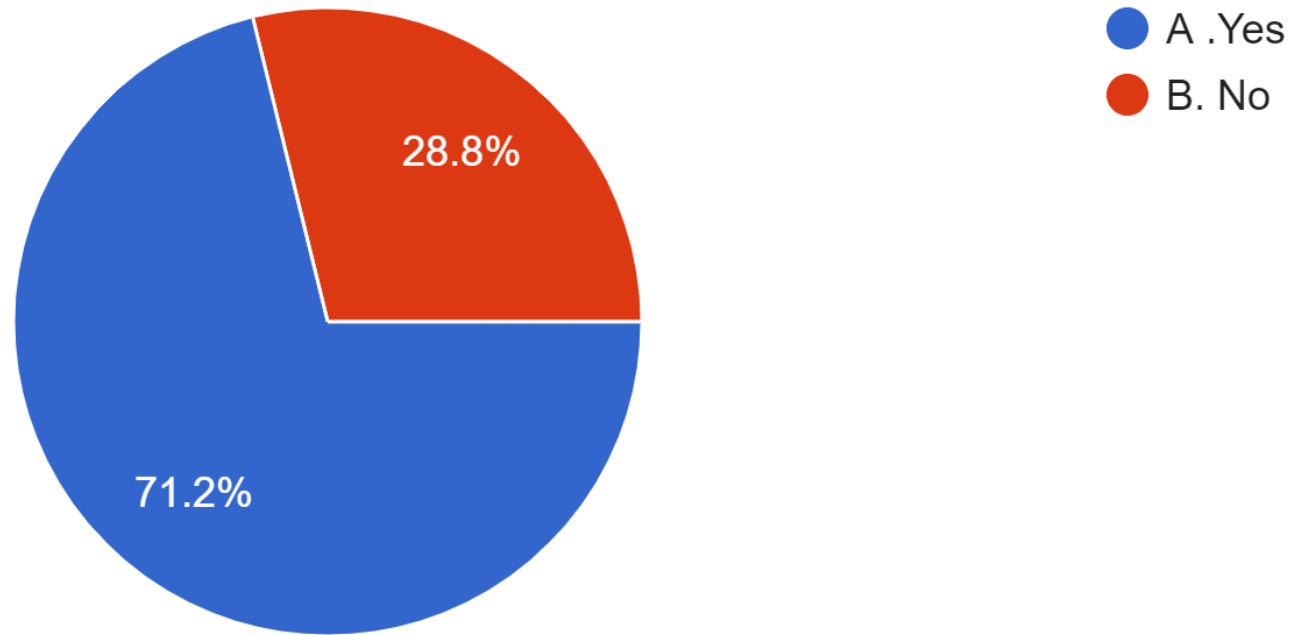
# 1- the hysteroscope you use on a daily basis for your infertile cases

52 responses



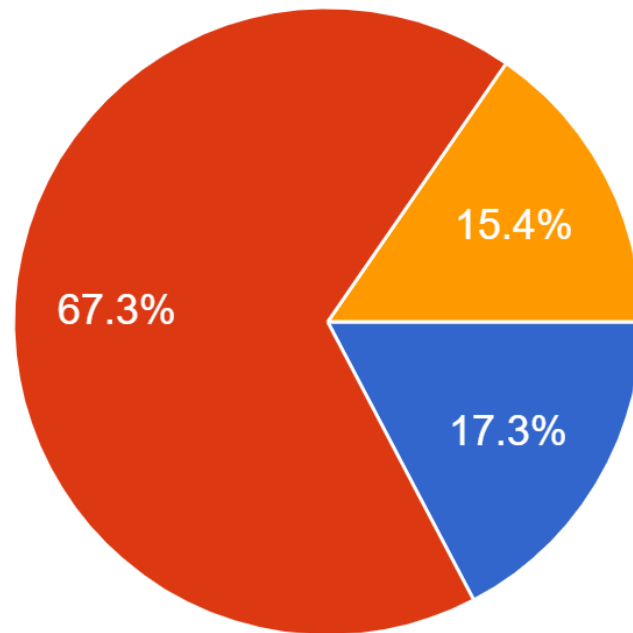
2- if you use office hysteroscopy , you adopt vaginoscopic approach without vulsellum or sound?

52 responses



### 3- you do office hysteroscopy before the first trial of ICSI

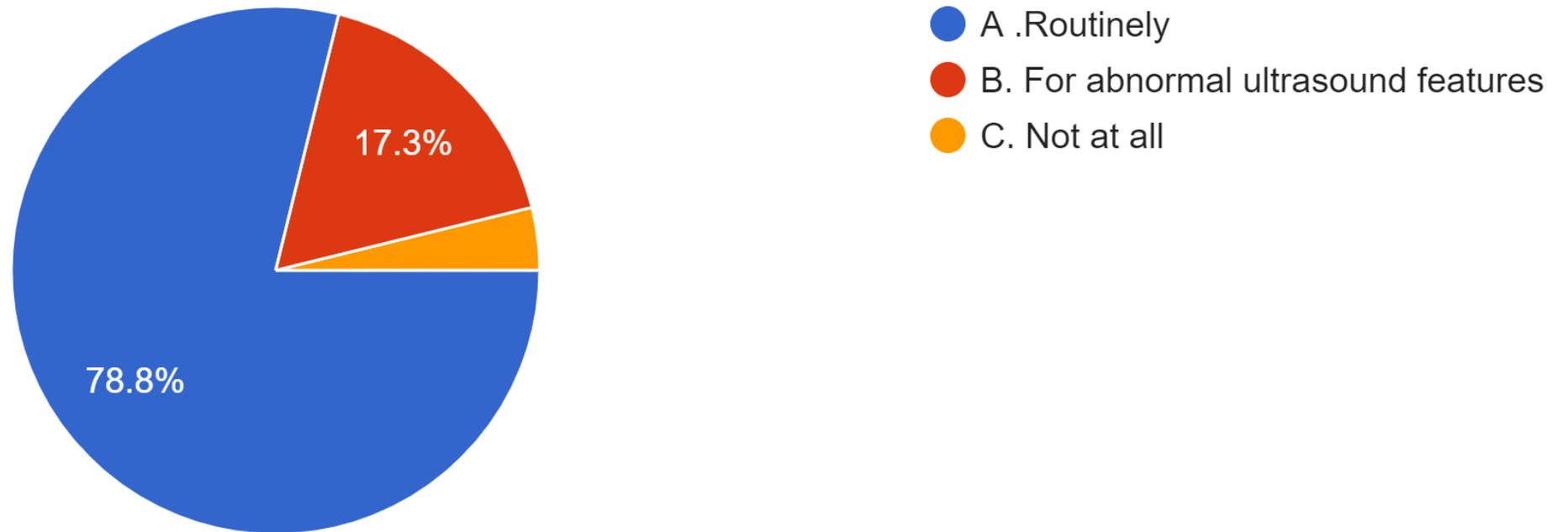
52 responses



- A. Routinely
- B. For abnormal ultrasound features
- C. Not at all

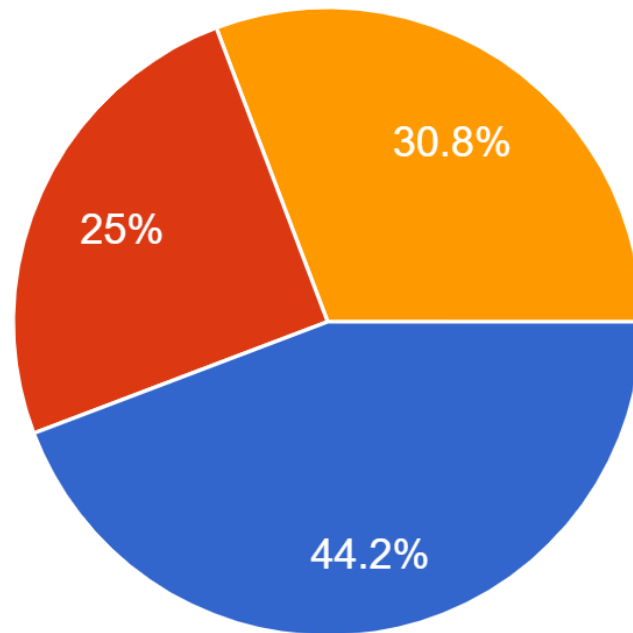
## 4-you do office hysteroscopy before trial of ICSI in RIF case

52 responses



## 5- you do hysteroscopic septum resection

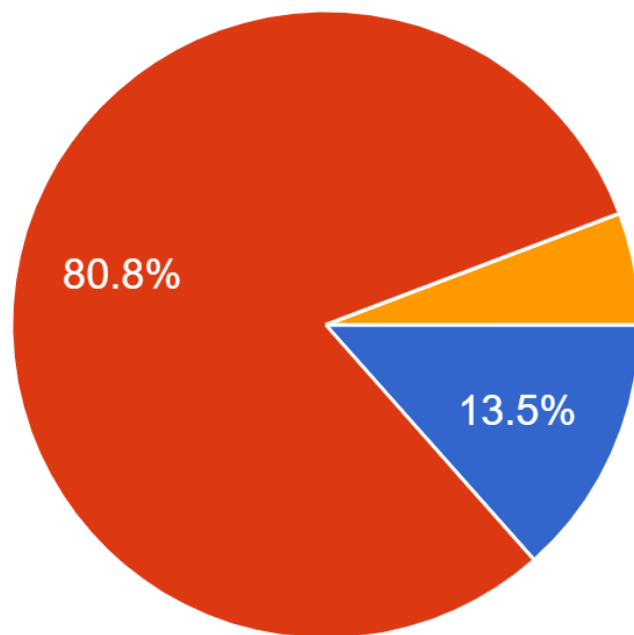
52 responses



- A. In any case with incomplete uterine septum
- B. In cases of RIF
- C. Before the first ICSI trial

6- in your practice hysteroscopic niche resection is done for :

52 responses

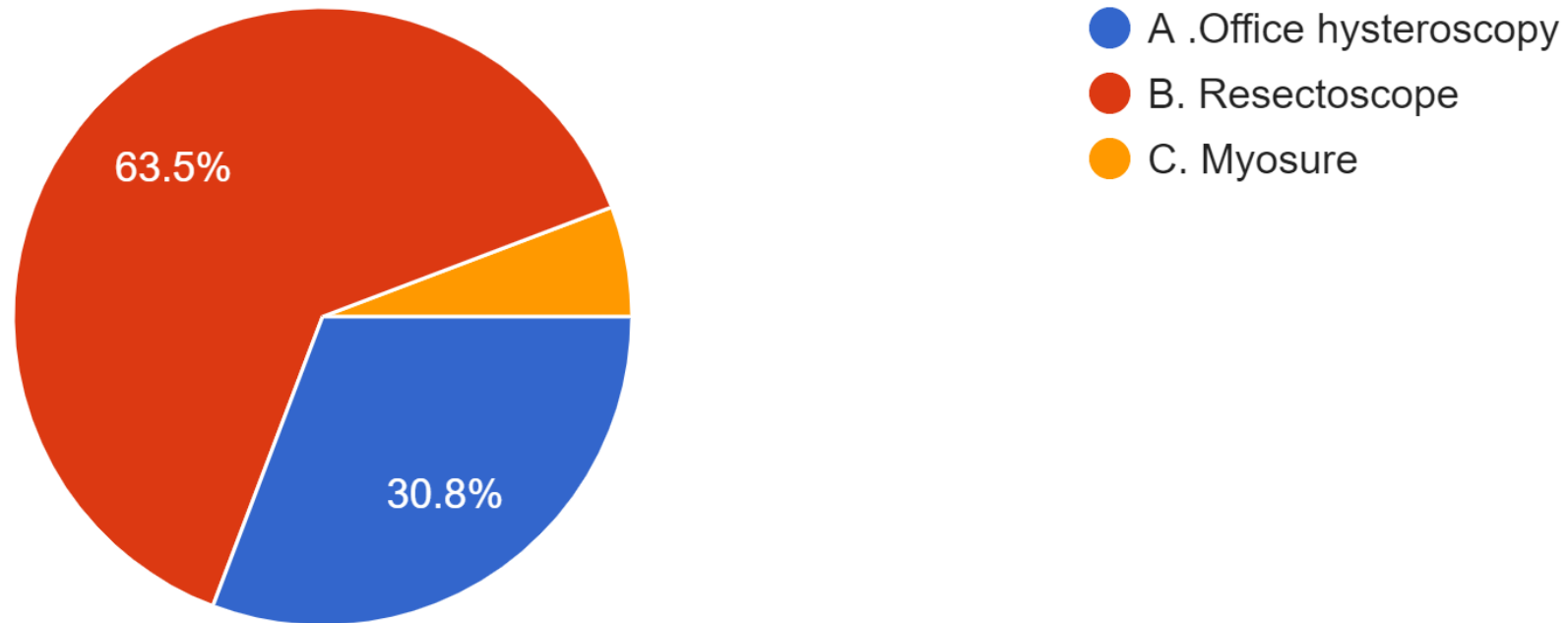


- A .All infertile women with unexplained infertility
- B. Women complaining of Infertility with postmenstrual spotting
- C. Routine before any IVF case



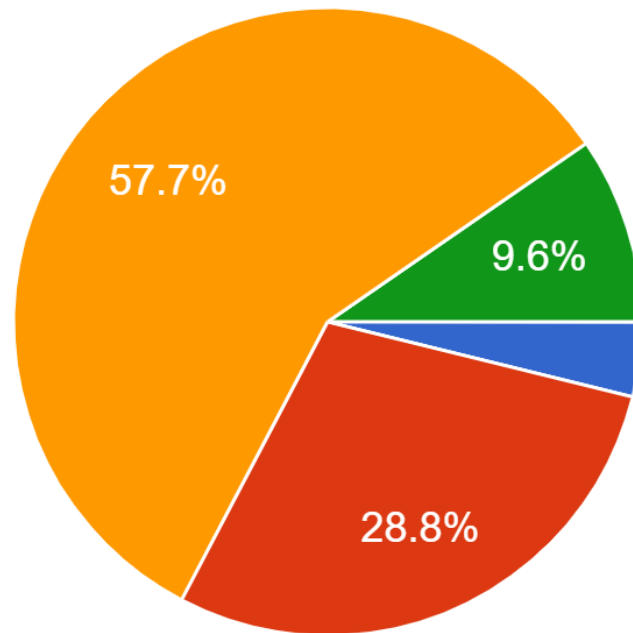
7- in your opinion cases with intrauterine adhesions is best managed with:

52 responses



8- for prevention of intrauterine adhesions you use which of the following:

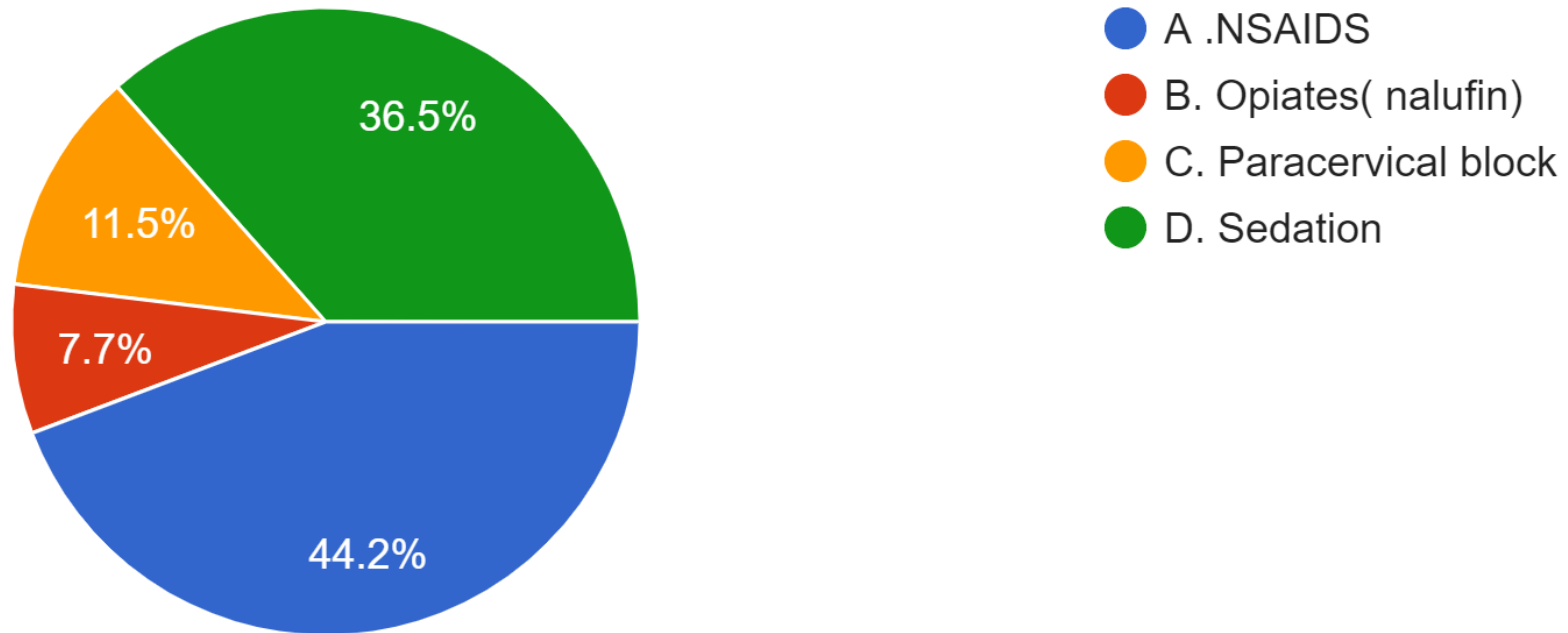
52 responses



- A. Intrauterine infusion of hyaluronic acid
- B. Insertion of non medicated IUD
- C. Cyclic Estrogen and progestetone
- D. Foley's catheter

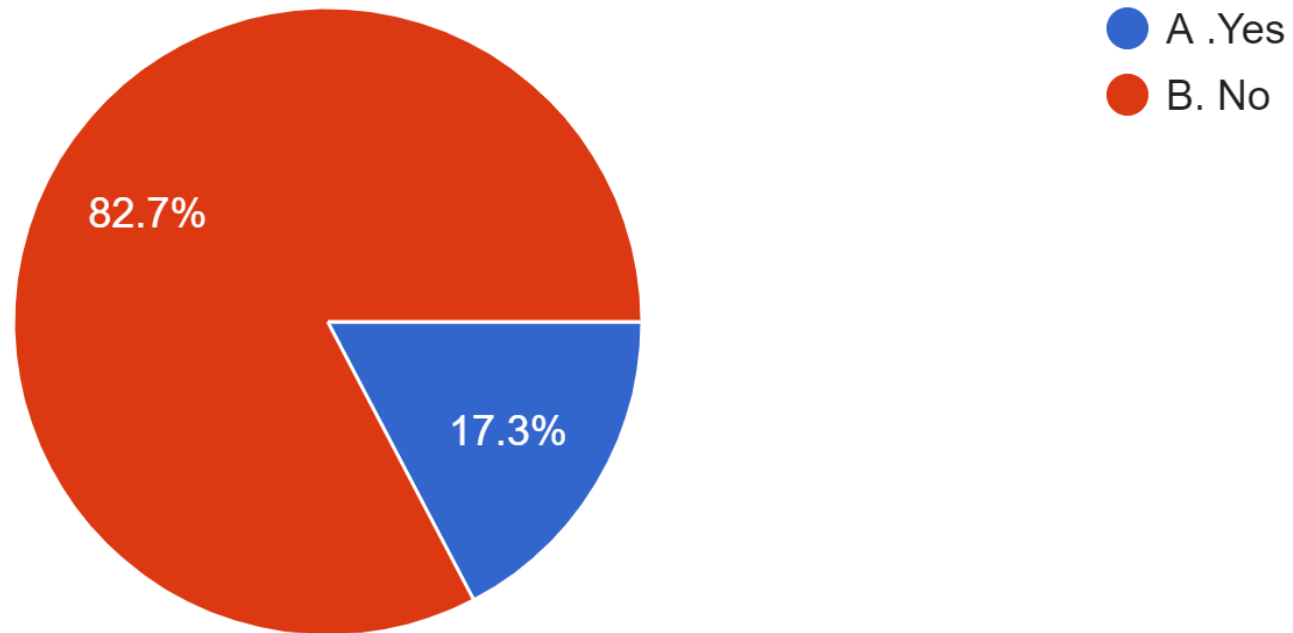
## 9- which type of analgesia you use for office hysteroscopy

52 responses



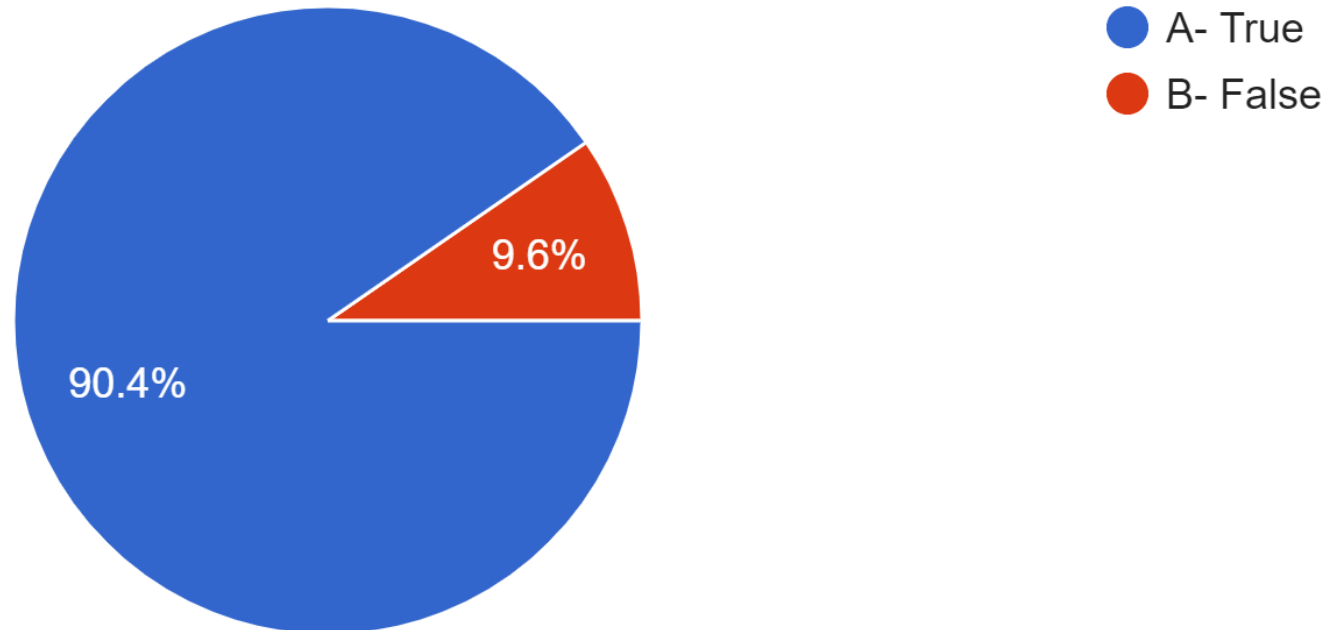
10- before hysteroscopic myomectomy, do you use Gnrh agonist or antagonist?

52 responses



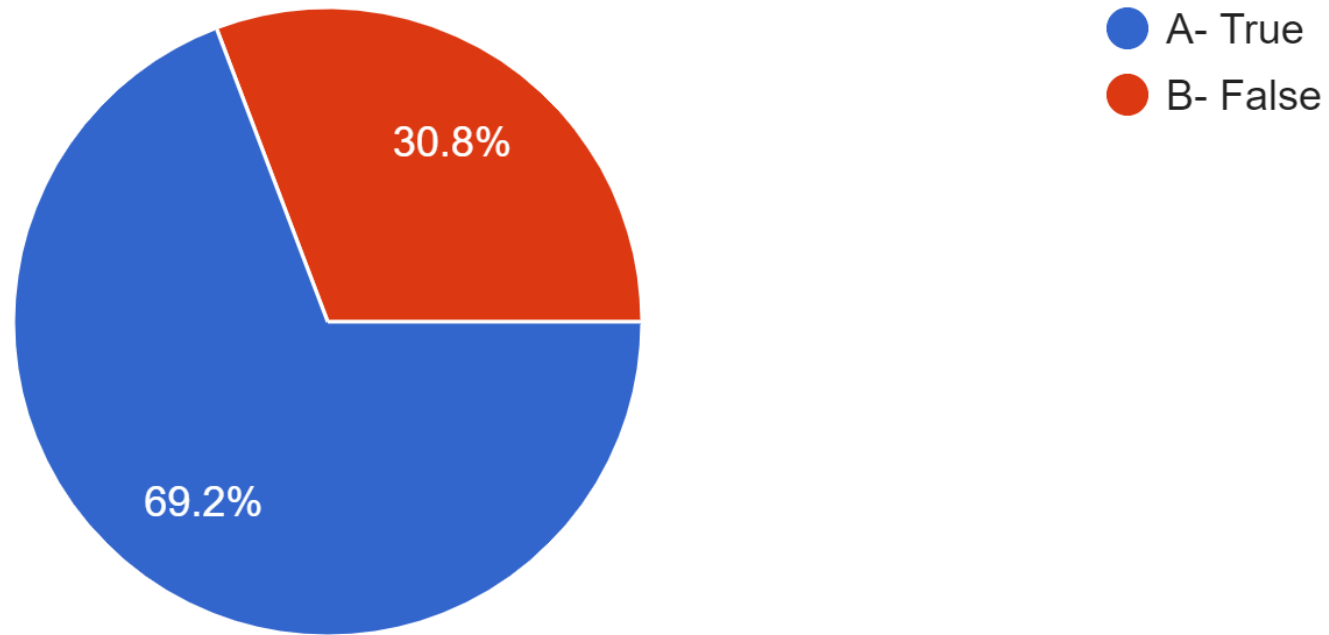
# 11- Using Normal saline as a distension medium allows for more fluid deficit safety range than with Glycine solution

52 responses



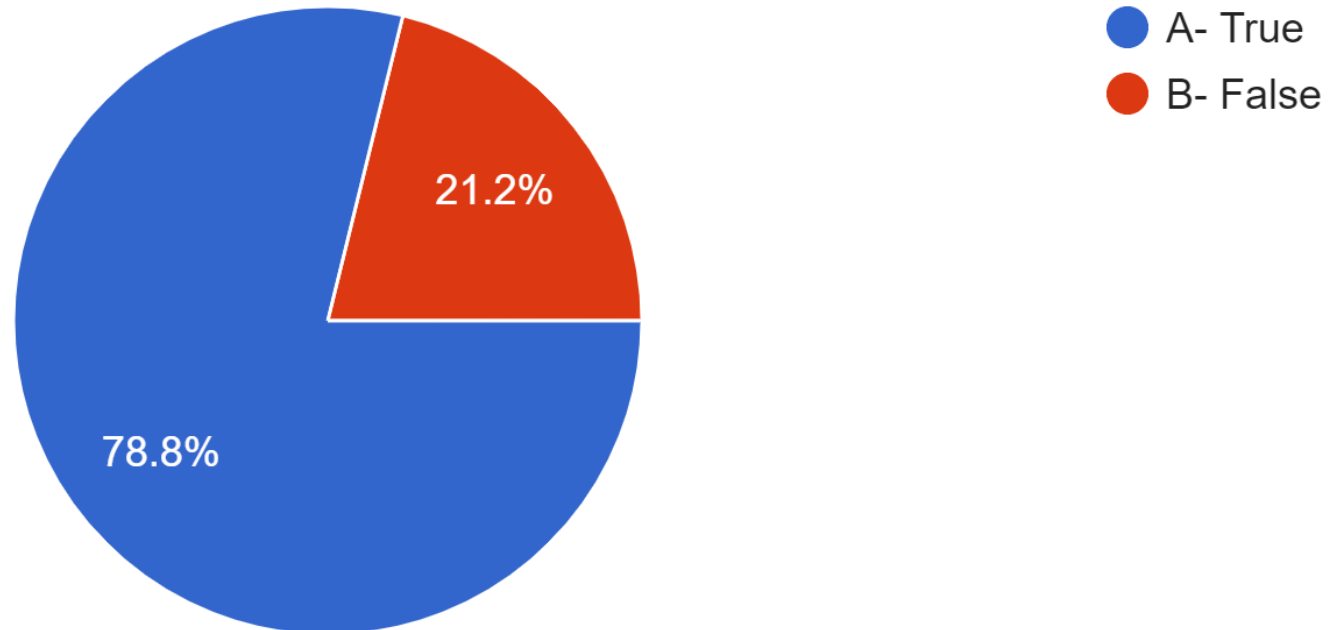
## 12- Type 2 submucous fibroids are suitable for hysteroscopic resection

52 responses



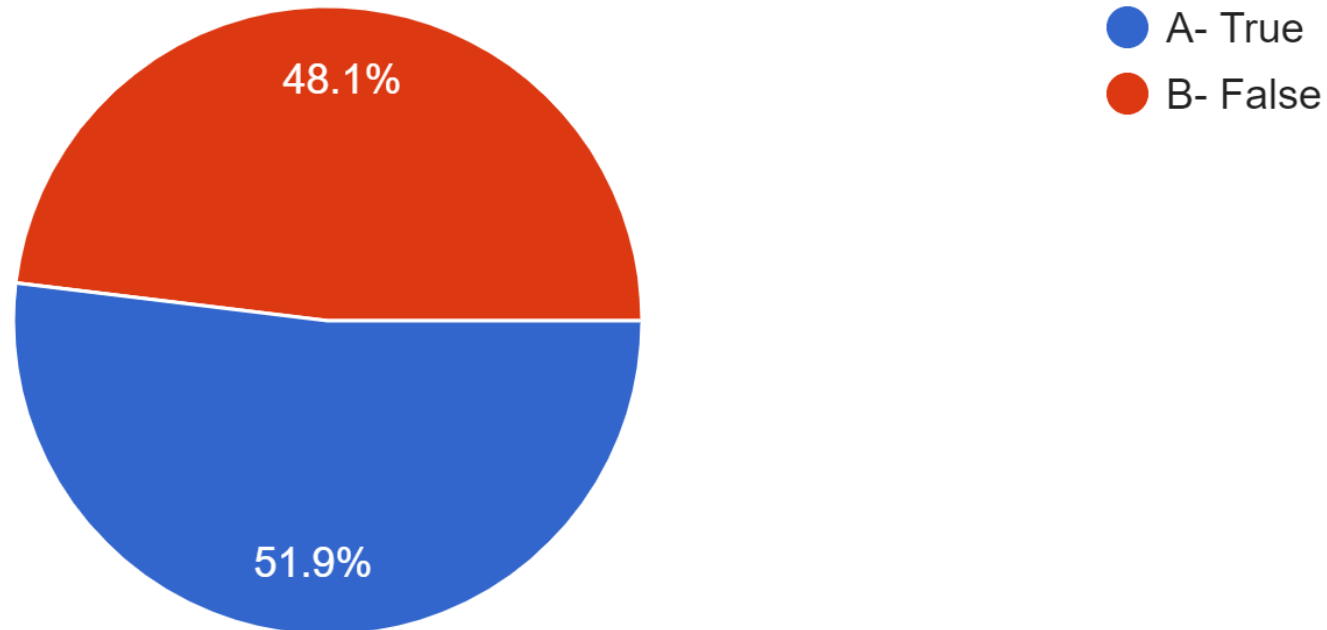
13- Submucous leiomyomas contribute to infertility, and although their removal improves pregnancy rates, the fertility rate remains lower than is the case for women with normal uteri.

52 responses



14 - Endometrial ablation can be an effective therapy for selected women with type 2 leiomyomas and HMB who do not wish to become pregnant in the future.

52 responses





15 - Do you think that chronic endometritis has a role in RIF and should be screened before IVF in these cases?

52 responses

